





# PARS PLANA VITRECTOMY IN THE TREATMENT OF RHEGMATOGENOUS RETINAL DETACHMENT

Chrapek Oldřich<sup>1,2</sup>, Matušková Veronika<sup>1,2</sup>, Vysloužilová Daniela<sup>1,2</sup>, Beránek Jan<sup>1,2</sup>, Souček Jan<sup>1,2</sup>, Sičová Kristína<sup>2</sup>, Březík Michal<sup>2</sup>

<sup>1</sup>Eye Clinic, University Hospital Brno, Czech Republic

<sup>2</sup>Eye Clinic, Faculty of Medicine, Masaryk University Brno, Czech Republic

*The authors of the study declare that no conflict of interests exists in the compilation, theme and subsequent publication of this professional communication, and that it is not supported by any pharmaceuticals company. The study has not been submitted to any other journal or printed elsewhere, with the exception of congress abstracts and recommended procedures.*

*Presented at the 30<sup>th</sup> Annual Congress of the Czech Ophthalmology Society in Brno, 2022*

Submitted to the editorial board: November 1, 2023

Accepted for publication: November 17, 2023

Available on-line: January 30, 2024



Doc. MUDr. Oldřich Chrapek, Ph.D.  
Slunečná 820/1D  
779 00 Olomouc  
E-mail: chrapek.oldrich@fnbrno.cz

## SUMMARY

**Aim:** The aim of the study is to retrospectively evaluate the anatomical success rate and functional results of 25G+ PPV in the treatment of newly diagnosed rhegmatogenous retinal detachment (RRD).

**Material and Methods:** The set consists of 152 eyes of 152 patients, of which 71 (47%) were men, average age 54 years, operated on by one surgeon for RRD at the Eye Clinic of the University Hospital and Medical Faculty of Masaryk University Brno from 1.7.2019 to 4.5.2021 using the 25G+ PPV technique. 25G+ PPV with pre-equatorial cerclage was performed on 7 patients. The patients' anamnesis included blunt ocular trauma and uncomplicated cataract surgery with implantation of a posterior chamber intraocular lens. The cause of RRD was retinal tear/s, regardless of their number and location. The transparency of the anterior segment of the eye enabled reliable visualization of the posterior segment. Preoperative proliferative vitreoretinopathy (PVR) grade A-D2 was admissible. Patients with a history of penetrating ocular trauma were excluded. The postoperative findings and functional outcomes of the patients were evaluated 1–3 months after PPV. The operation was anatomically successful if the retina was fully attached. Final visual acuity (VA) was evaluated for each patient. The final visual acuity examination was carried out typically on a Snellen optotype, either without correction, with the patient's own spectacle correction or with correction according to the current values on the autorefractometer. The arithmetic average was used for the numerical expression of the attained results, and the numerical values were also expressed in percentages. Since the different groups were not compared with each other, no statistical test was necessary to analyze the results.

**Results:** In 150 (98.7%) of the 152 patients in the group, we achieved complete retinal reattachment, in 2 (1.3%) patients the retina remained detached, and we recorded anatomical failure of the treatment. Fifty (33%) patients achieved VA  $\geq$  4/8.

**Conclusion:** In 133 (87.5%) patients, we are able to state anatomical success even without the presence of intraocular tamponade in the operated eye. These patients can be considered completely cured. 25G+ PPV has demonstrated its contribution to resolving RRD.

**Key words:** rhegmatogenous retinal detachment, visual acuity

Čes. a slov. Oftal., 80, 2024, No. 1, p. 12–15

## INTRODUCTION

Rhegmatogenous retinal detachment (RRD) refers to the separation of the neurosensory layer of the retina from the retinal pigment layer due to a tear or hole. This then enables the ingress of fluid through this tear or hole into the subretinal space, causing a mutual detachment of both layers of the retina. This relatively simple and brief definition of retinal pathology covers countless variable findings and conditions. RRD can be treated by 3 basic types of procedures. In the 1950s Schepens referred to the use of cryosurgical techniques, with the application of episclerally fixed cerclage bands and seals [1,2]. Around the turn of the 1970s, Machemer

introduced pars plana vitrectomy (PPV) [3]. In 1986 Hilton and Grizzard referred to pneumatic retinopexy as a third option for treating RRD [4].

The overall aim of this study is to retrospectively evaluate the anatomical success rate and functional results of PPV in the treatment of newly diagnosed and as yet untreated RRD in patients operated on at the Eye Clinic of the University Hospital Brno in the period from 1 July 2019 to 4 May 2021 using the 25G+ PPV technique. The first objective is to assess the success rate of the performed primary operations, the second objective is to evaluate the success rate of the definitive reattachment of the retina. The third objective is to evaluate the patients' resulting postoperative visual acuity (VA).

## MATERIAL AND METHODS

The evaluated cohort comprised patients with RRD. The patients' anamnesis could include blunt ocular trauma and uncomplicated cataract surgery with implantation of a posterior chamber intraocular lens. The cause of retinal detachment was retinal tear/s regardless of their number and localization. The transparency of the cornea and anterior segment of the eye enabled reliable visualization of the posterior segment of the eye. The evaluated cohort also included patients in whom pre-operative proliferative vitreoretinopathy (PVR) grade A-D2 had been diagnosed. Patients who had previously suffered penetrating ocular trauma were excluded.

The surgical treatment for RRD applied to the patients was three-port 25G+ PPV consisting in the complete removal of the vitreous body, identification of retinal tears, according to the perioperative finding peeling of the epi/subretinal membranes, temporary perioperative stabilization of the detached retina by air or liquid perfluorocarbon, treatment of the retinal tears by endolaser photocoagulation or exocryocoagulation, and intraocular tamponade with expansive gas or silicone oil (SO). Non-expansive concentrations of sulfur hexafluoride (20% SF<sub>6</sub>) or octafluoropropane (16% C<sub>3</sub>F<sub>8</sub>) gas were used. The most commonly used type of silicone oil was SO with a density of 1300 Cts. In the case of very complicated findings, cerclage was used during 25G+ PPV by means of the suturing of a cerclage band with a width of 2 mm in the pre-equatorial position, with the anterior edge of the band 11 mm from the corneal limbus.

The patients were assessed 1 to 3 months after surgery. An examination of the ocular fundus was conducted on the patients biomicroscopically and by indirect ophthalmoscopy. The operation was considered anatomically successful if the retina was fully attached, thus if contact of the neuroepithelium and retinal pigment layer was restored on the posterior pole and throughout the entire periphery. The operation was considered anatomically unsuccessful if persistent separation of the neuroepithelium from the pigment layer was determined at least in part (on the posterior pole or on the retinal periphery). Resulting (postoperative) VA was evaluated for each patient, examined as natural VA and VA with the patient's own spectacle correction. If natural VA or VA with the patient's own correction in the postoperative period did not appear to be satisfactory, for example following implantation of SO, spectacle correction according to the current values on the autorefractometer was used to determine resulting VA. Examination of VA was performed on a Snellen optotype. We evaluated the patient's resulting VA as the best VA attained within the period of 1–3 months after surgery.

The arithmetic average was used for the numerical expression of the attained results, and the numerical values were also expressed in percentages. Since the different groups were not compared with each other, no statistical test was necessary to analyze the results.

The cohort consisted of 152 eyes of 152 patients, of whom 71 (47%) were men and 81 (53%) were women, with an average age of 54 years, operated on by one surgeon for RRD at the Eye Clinic of the University Hospital and Medical Faculty of Masaryk University Brno from 1.7.2019 to 4.5.2021 using the 25G+ PPV technique. 25G+ PPV with pre-equatorial cerclage was performed on 7 patients. In 68 cases (45%) the right eye was afflicted, in 84 cases (55%) the left eye. All the patients were operated on under general anesthesia.

## RESULTS

A single 25G+ PPV procedure was sufficient to achieve reattachment of the retina in 129 (85%) patients, in 23 (15%) patients the retina was not reattached, therefore the primary operation was unsuccessful. These 23 unsuccessfully operated patients were reoperated on. The 25G+ PPV technique was used for reoperation, in 21 cases reattachment of the retina was achieved, in 2 cases the procedure was again unsuccessful. Overall we are able to state that out of 152 patients in the cohort, in 150 (98.7%) we achieved definitive retinal reattachment throughout its entire scope, and therefore definitive anatomical success, while in 2 (1.3%) patients the retina remained detached and we concluded anatomical failure of the treatment.

A single 25G+ PPV procedure was sufficient to achieve reattachment of the retina in 129 (85%) patients. Of these 129 patients, 25G+ PPV with intraocular gas tamponade was performed on 106 patients, and silicone oil (SO) tamponade on 23 patients.

The 23 originally unsuccessfully operated patients were reoperated on. In the case of 17 patients, single 25G+ PPV was performed as the reoperating procedure (re-PPV). Of these 17 patients, re-PPV was finished with gas tamponade in 4 patients, while silicone oil tamponade was used in re-PPV in 13 patients. Two 25G+ PPV procedures were used for reoperation on 6 patients. In one of these 6 patients, the first re-PPV procedure was finished with intraocular gas tamponade, but due to repeat failure the second re-PPV procedure was performed with implantation of SO. In the remaining 5 patients, both the first and the second re-PPV procedure were finished with implantation of SO. Only 6 patients underwent three PPV procedures, one primary and two re-PPV. None of the patients in the cohort underwent more than 3 PPV procedures.

It is possible to state that out of 152 patients in the cohort, in 110 (72%) patients either primary PPV or re-PPV was finished with gas intraocular tamponade. In 42 (28%) patients primary PPV or re-PPV was finished with implantation of SO. At the end of the follow-up and evaluation period (4 May 2021), SO had been successfully evacuated in 23 patients – after evacuation of SO the retina remained attached throughout its entire scope. In 19 patients SO was still present in the vitreous cavity at the end of the observation period. Of these 19 patients,

anatomical success was achieved in 17 cases using SO tamponade, and in 2 patients we concluded anatomical failure of the treatment.

The resulting VA in the postoperative period is illustrated in Graph 1. 50 (33%) patients attained VA ZO  $\geq$  4/8. In 140 (92%) patients we conclude VA  $\geq$  4/40. In the 2 patients in whom we did not achieve anatomical success, the result was VA = 0.

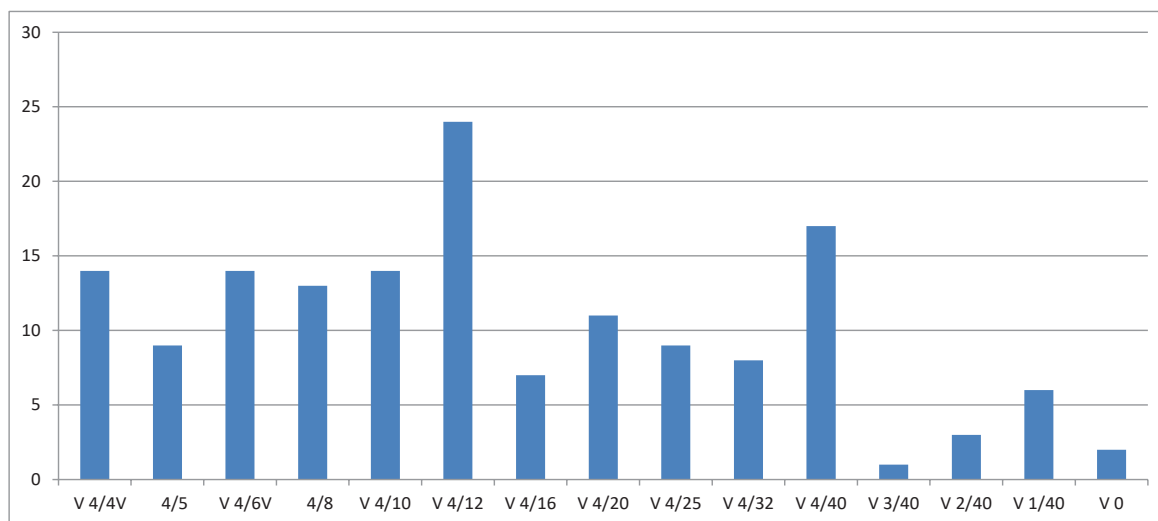
## DISCUSSION

Three therapeutic procedures are currently considered in the treatment of RRD: pneumatic retinopexy, cryosurgical techniques and PPV. However, pneumatic retinopexy is indicated only in the case that retinal detachment is caused by a single tear, which is localized in the upper periphery between numbers 8 and 4 on the clockface, and the extent of this tear is maximally within the range of one perimeter hour [4]. Tornambe states that primary anatomical success is achieved in only 75% of phakic and 67% of arthphakic eyes [5]. For the above reasons, the use of pneumatic retinopexy in the treatment of RRD is limited, and doctors mostly decide in favor of either cryosurgical techniques or PPV. No clear boundary exists between the use of a cryosurgical procedure and PPV. The reason for this is the high variability of the clinical finding associated with the diagnosis of RRD, which on one hand may mean the presence of uncomplicated, localized retinal detachment with a single tear, and on the other hand may mean total retinal detachment with multiple tears and preoperative PVR. With regard to the complexity of the preoperative clinical finding, it is possible to concur with the practice of dividing patients into three basic groups, as in the case of the study conducted by Feltgen [6]. In this study, Feltgen observed localized retinal detachment (within the scope of 4 perimeter hours) with a single tear or adjacent tears in 50% of patients. The majority of these patients received cryosurgical treatment [6]. At the op-

posite end of the spectrum of clinical findings were 20% of patients with complicated findings with PVR grade B and C, large tears, macular holes, for whom indication for PPV predominated [6]. Between these two poles of the cohort, Feltgen observed 30% of patients with a medium-severe finding. In this group he classified patients with multiple tears in various quadrants, bullous retinal detachment, tears spreading centrally beyond the equator, tears with marked retinal traction and patients with RRD with an unclear situation of the edges of the tears (preoperatively without a finding of tears or in whom preoperative identification of all tears was impossible). On this group of patients PPV or cryosurgery was used, or a combination of both [6]. We did not select the patients for our cohort in a targeted manner, and therefore the patients in our cohort corresponded to all three groups defined above by Feltgen.

Joseph evaluated a multicentric retrospective study of the anatomical and functional results of PPV, as well as PPV combined with buckling techniques on a cohort of 893 pseudophakic eyes with RRD [7]. PPV was performed on 684 (77%) eyes, and PPV in combination with buckling techniques on 209 (23%) eyes. Success of the primary operation is stated in a total of 770 (86%) eyes, of which 577 (84%) in the group operated on using simple PPV, and 192 (92%) in the group operated on using the technique of PPV in combination with buckling procedures. Average resulting VA in the patients who had an attached macula before surgery was 20/32, and in the patients in whom the macula was detached before surgery average resulting VA was 20/64.

We are of the opinion that we attained comparable results in our own cohort. In 129 (85%) patients we achieved reattachment of the retina using a single 25G+ PPV procedure. We achieved definitive retinal reattachment in 150 (98.7%) patients. Out of our cohort of 152 patients, in 145 (95%) we performed simple 25G+ PPV. In only 7 (5%) patients we performed pre-equatorial cerclage as part of primary 25G+ PPV. The



**Graf 1.** Dosažené úrovně zrakové ostrosti v pooperačním období  
V – zraková ostrost

reason for combination of 25G+ PPV with the suturing of a cerclage band was the position and number of retinal tears in RRD of the inferior quadrants, in which we decided in favor of suturing a cerclage band in patients with at least one tear in the periphery of both inferior quadrants, thus minimally with one tear which was simultaneously to the left and to the right of the vertical meridian of number 6. In the subgroup with 25G+ PPV we attained success of the primary operation in 122 (84%) eyes, in the subgroup in which we combined 25G+ PPV with pre-equatorial cerclage we achieved success of the primary operation in all 7 (100%) eyes. We are aware that this result may be influenced by the error factor of a small cohort. In our cohort average resulting VA of the patients was 4/10, which corresponds to a value of 20/50. In our cohort, we did not evaluate the resulting VA of patients in whom the macula was attached prior to PPV separately from the resulting VA of patients in whom the macula had been detached before PPV. We believe that the resulting value of VA of the patients in our cohort lies between the values of resulting VA mentioned by Joseph for his two subgroups precisely for this reason.

## CONCLUSION

We can state that in 133 (87.5%) of the patients in our cohort we achieved anatomical success without the presence of intraocular tamponade in the operated eye. Anatomically these patients can be considered entirely cured. In the case of 17 patients, although we can conclude anatomical success of the treatment, this came at the price that SO remained present in their vitreous cavity. In the case of these patients, we therefore cannot speak of definitively successful treatment of RRD. Assessing the degree of anatomical success or failure in this subgroup of patients requires further observation, with an evaluation of the relevant number of findings of reattached retina after the definitive evacuation of SO in future. In 2 (1.3%) patients, retinal detachment remained even despite repeated 25G + PPV. From this follows on their functional result, in which VA in these 2 patients is equal to 0. On the other hand, it is necessary to emphasize that 33% of patients attained resulting useful VA of 4/8 and better. Overall, we therefore evaluate 25G+ PPV as an effective method of treating RRD in newly diagnosed and as yet untreated/unoperated patients.

## REFERENCES

1. Schepens CL. Progress in detachment surgery. *Trans Am Acad Ophthalmol Otolaryngol* 1951;55:607-615.
2. Schepens CL, Okanuta ID, Brockhurst RJ. The scleral buckling procedures. I. Surgical techniques and management. *AMA Arch Ophthalmol* 1957;58:797-811.
3. Machemer R, Parel JM, Buettner H. A new concept for vitreous surgery. I. Instrumentation. *Am J Ophthalmol* 1972;73:1-7.
4. Hilton GF, Grizzard WS. Pneumatic retinopexy. A two-step outpatient operation without conjunctival incision. *Ophthalmology* 1986;93:626-641.
5. Tornambe PE, Hilton GF. The Retinal Detachment Study Group. A multicenter randomized controlled clinical trial comparing pneumatic retinopexy with scleral buckling. *Ophthalmology* 1989;96:772-784.
6. Feltgen N, Weiss C, Wolf S et al. Scleral buckling versus primary vitrectomy in rhegmatogenous retinal detachment study (SPR Study): recruitment list evaluation. Study report no. 2. *Graefes Arch Clin Exp Ophthalmol* 2007;245:803-809.
7. Joseph DP, Ryan EH, Ryan CM et al. Primary Retinal Detachment Outcomes Study: Pseudophakic Retinal Detachment Outcomes. *Ophthalmology* 2020;127:1507-1514.