

THE CURRENT POSSIBILITIES OF OPHTHALMOLOGICAL DIAGNOSIS AND CO-OPERATION BETWEEN OPHTHALMOLOGISTS AND NEUROLOGISTS FOR PATIENTS WITH IDIOPATHIC INTRACRANIAL HYPERTENSION

SUMMARY

Purpose: The aim of this paper is to present the current possibilities in idiopathic intracranial hypertension (IIH) diagnostics. Optical coherence tomography belongs to these possibilities in last few years. The necessary interdisciplinary co-operation of ophthalmologist and neurologist concerning in IIH patients is pointed out in the mentioned case reports.

Material and methods: The issue of diagnostics and care of IIH patients is presented in two case reports.

Results: After ophthalmological and neurological examination the diagnosis of idiopathic intracranial hypertension was assessed and the treatment with acetazolamide was started. The patients have been observed in The department of ophthalmology University hospital in Pilsen during the run of the disease by the neuroophthalmologist. The edema of optic nerve has been monitored by fundoscopy and optical coherence tomography. Initially highly distended retinal nerve fiber layer thickness has been decreased with the normalizing of optic nerve head appearance. The patient's difficulties have gone off during couple of month and the edema of optic nerve papilla has disappeared. According to the education and the regime acquisition our two patients reduced their body weight, so that they influenced favourably the development of their disorder.

Conclusion: IIH is consequential disorder causing patient's crucial restriction in an ordinary lifestyle. It could cause difficult changes in vision. The early diagnosis and proper leading of the therapy is fundamental for the next development of patient's health.

Key words: idiopathic intracranial hypertension, optical coherence tomography, edema of optic nerve head, papilloedema

Čes. a slov. Oftal., 72, 2016, No. 2, p. 32–38

INTRODUCTION

Idiopathic intracranial hypertension (IIH) is defined as a condition in which there is an increase in pressure of laboratory normal coeliolymph due to unknown causes, with a normal finding on computer tomography (CT) with a contrast substance or on magnetic resonance (MR) of the head (2, 5, 12). All of this is with a physiological neurological finding, with the exception of paresis of the 6th head nerve. The first cases of patients with IIH was described by Quincke, who mentioned high pressure of coeliolymph shortly after performing lumbar puncture in 1897. In medical terminology this condition has also been referred to for many years as pseudotumor cerebri. In 1995 Foley identified high coeliolymph pressure of indefinite etiology as benign intracranial hypertension. However, today this term has been abandoned due to published cases of patients with severe damage to sight (3, 20). The incidence of the pathology in the present population is 0.9 per 100 000, or 3.5 per 100 000 women per year. From the numerical values it clearly ensues that the pathology

afflicts women more, above all younger women with a high body mass index (BMI). In this group incidence increases up to 19/100 000 per year. Obesity is one of the main risk factors. The continuing increase in the incidence of obesity in our population is accompanied with an increased incidence of IIH (4, 16). IIH appears in adults, adolescents and less frequently also in pre-pubescent children (8). IIH may be closely linked with hormonal disorders, nutritional disorders, obstacles in venous outflow, conditions after meningitis upon subarachnoid haemorrhage, hypercoagulable states and others (13). The pathology has not only a neurological but also ophthalmological symptomatology. As a result an ophthalmologist may be the first specialist to be visited or may be requested for a consultation examination. In these patients we usually encounter a finding of bilateral papilloedema of the optic nerve (ON), which requires prompt differential diagnostic consideration with an indication of graphic examination. The aim of this study is to draw attention to the diagnostic procedure upon IIH with emphasis on the current possibilities of the use of optical coherence tomography (OCT) in order to monitor the

Kasl Z.¹, Rusňák Š.¹, Matušková V.², Peterka M.³, Sobotka P.³, Jirásková N.⁴

¹Department of ophthalmology, Faculty of Medicine in Plzeň, Charles University in Prague and University Hospital Plzeň, head: doc. MUDr. Renata Říčařová, CSc., FEBO

²Department of ophthalmology, Masaryk University and University Hospital Brno, head: prof. MUDr. Eva Vlková, CSc.

³Department of neurology, Faculty of Medicine in Plzeň, Charles University in Prague and University Hospital Plzeň, head: MUDr. Jiří Polívka, CSc.

⁴Department of ophthalmology, Faculty of Medicine in Hradec Králové, Charles University in Prague and University Hospital Hradec Králové, head: prof. MUDr. Naďa Jirásková, Ph.D., FEBO

The authors of the study declare that no conflict of interest exists in the compilation, theme and subsequent publication of this professional communication, and that it is not supported by any pharmaceuticals company.



as. MUDr. Zdeněk Kasl
Oční klinika Lékařské fakulty v Plzni
Univerzity Karlovy v Praze a Fakultní
nemocnice Plzeň
Alej Svobody 80, 304 60 Plzeň
Email: zdenekkasl@volny.cz

development of papilloedema of the ON and to accentuate the importance of mutual co-operation of the ophthalmologist and neurologist in determining the correct diagnosis and setting the optimal therapy.

CASE REPORT 1

In July 2013 at our centre we examined a fifteen year old girl with a body mass index (BMI) of 31.4, sent by her attending paediatrician due to feelings of specks in the visual field (VF) and transitory diplopia. In the patient's anamnesis there was subjective dominance of headaches persisting for several days during the course of May 2013 and more intensively in June 2013. Otherwise the girl was healthy. Central visual acuity in both eyes was 1.0 naturally, with intraocular pressure of 18/17 mm Hg. On the Full Field 81 (FF 81) perimeter of both eyes we found relative and absolute blind spots in the VF around the Marriott point. Upon examination the bulbs were in central position without apparent mobility disorder, and without diplopia. The pupils were isocoric, reacting to direct and indirect illumination. The further finding on the anterior segment was normal. In artificial mydriasis we observed the papillas of the optic nerve with massive edema on the ocular fundus (4th degree of Frisen scale bilaterally), a higher content of venous plexus peripapillary, with an otherwise normal finding on the retina. We performed measurement of the thickness of the retinal nerve fibre layer (RNFL) at the disc of the ON, originally on OCT Zeiss Stratus. An examination was also performed on a Hess screen and Maddox cross without demonstrating diplopia. Blood pressure was within the norm and according to the anamnesis the patient had never had complaints with blood pressure. We sent the patient for CT of the head.

CT examination of the brain and orbits was performed natively with the description: Brain parenchyma without deposit changes, mid-line structures without lateralisation. Chamber system of proportionate width. Skeleton without structural changes, calcification in falx, paranasal cavities free. Intraorbitally without signs of expansion, normal width of extraocular muscles, normal appearance of both eyeballs.

The patient was sent with the result of the CT to the Department of Paediatric Neurology at the Neurological Clinic, University Hospital Plzeň. Lumbar puncture (LP) was performed with reported normal effusion pressure, with physiological composition of coeliolymph and normal topical neurological finding. Following consultation with our centre and familiarisation with the massive scale of edema, the neurologist did not exclude the possibility of originally higher pressure of coeliolymph, which was not recorded at the LP examination. With regard to the anamnesis, subjective complaints and finding of papilloedema in both eyes, the constitution of the patient 165 cm/85 kg and normal finding on the head graphics, a diagnosis of IIH was determined following an agreement with neurologists, and acetazolamide therapy in a dose of 750 mg/day was commenced at the Department of Ophthalmology, University Hospital Plzeň. At an examination after only 3 weeks of treatment there was an evident effect in the objective finding on the papilla of the ON, on the perimeter and on OCT. With regard to the good effect of the re-

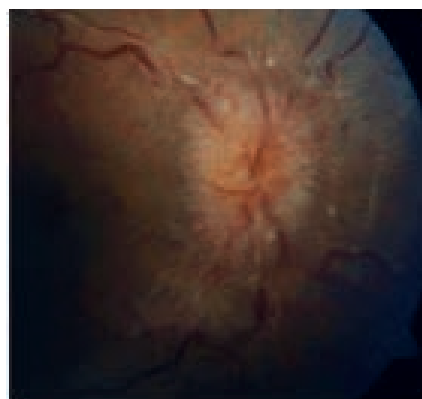


Fig. 1 Disc of optic nerve upon first examination in right eye

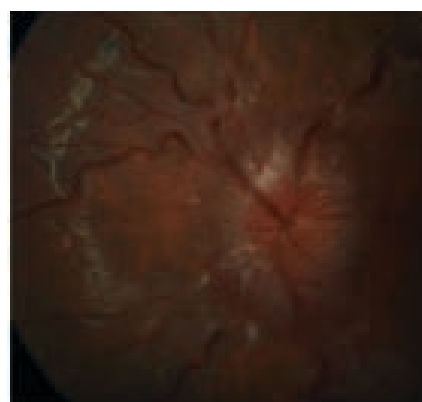


Fig. 2 Disc of optic nerve upon first examination in left eye

latively low initial dose we continued in this dose throughout August 2013, and due to the constantly improving finding the dose was reduced in September 2013 to 500 mg/day, and during the course of October to 250 mg/day. The treatment was performed at the Department of Ophthalmology and consulted continuously with paediatric neurologists.

Due to the normalised finding on the papillas of the ON, subjective improvement to the norm and objectively normal finding, acetazolamide therapy was discontinued at the end of November 2013. The patient was observed further at monthly to two monthly intervals until February 2015. Since that time we have been observing the patient regularly at an interval of several months, including examination of the visual field. The patient is entirely without ocular complaints. She repeatedly states in response to targeted questioning that she does not suffer from headaches. The finding of subsided edema of the disc of the optic nerve bilaterally is documented by examination on OCT Heidelberg Spectralis, on which stable thickness of the RNFL with practically normal values is recorded at the last follow-up examinations. The patient has a normalised VF in both eyes. During treatment the patient succeeded in losing eight kilograms.

CASE REPORT 2

A thirty six year old woman with a BMI of 30.1 was examined at the neurological outpatient clinic for headaches persi-

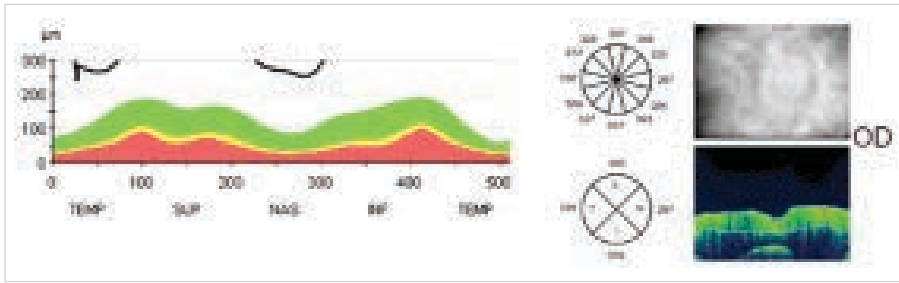


Fig. 3 Baseline measurement of retinal nerve fibre layer for monitoring papilloedema of optic nerve originally on optical coherence tomography Stratus Zeiss in right eye

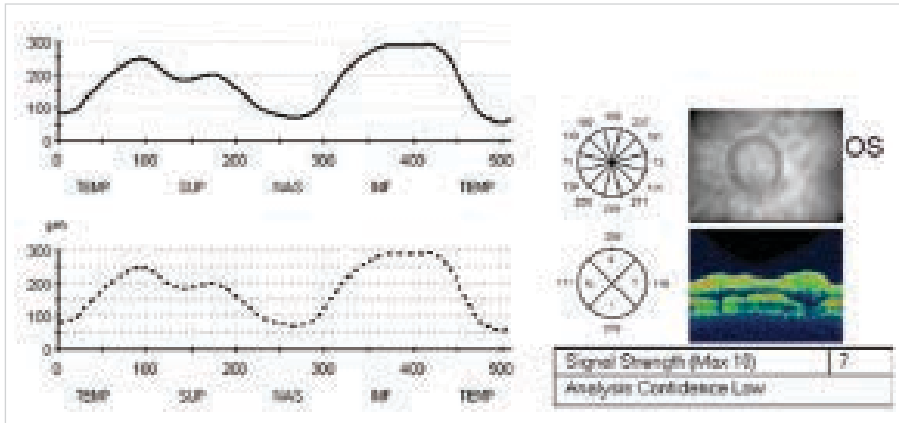


Fig. 4 Baseline measurement of retinal nerve fibre layer for monitoring papilloedema of optic nerve originally on optical coherence tomography Stratus Zeiss in left eye




Fig. 5 Baseline parametric examination with extension of Marriott point in left eye




Fig. 6 Baseline parametric examination with extension of Marriott point in right eye

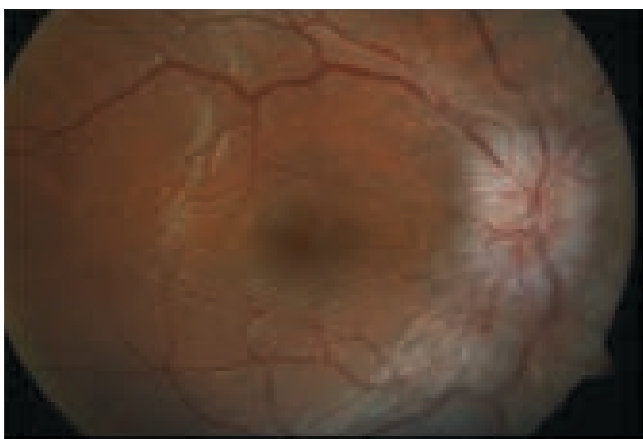

Fig. 7 Improving finding with regressing edema of disc of optic nerve in right eye after a few weeks of therapy

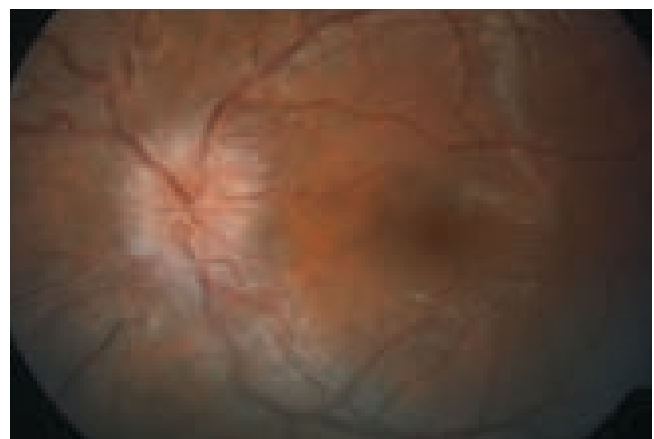


Fig. 8 Improving finding with regressing edema of disc of optic nerve in left eye after a few weeks of therapy

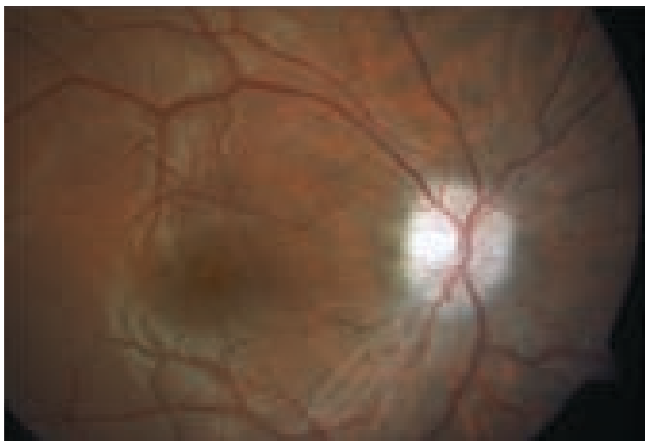


Fig. 9 After four months of therapy there was a further subsidence of edema of the disc of the optic nerve in the right eye

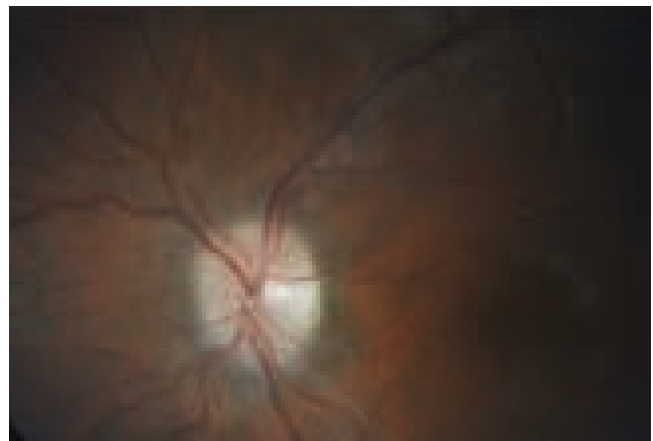


Fig. 10 After four months of therapy there was a further subsidence of edema of the disc of the optic nerve in the left eye

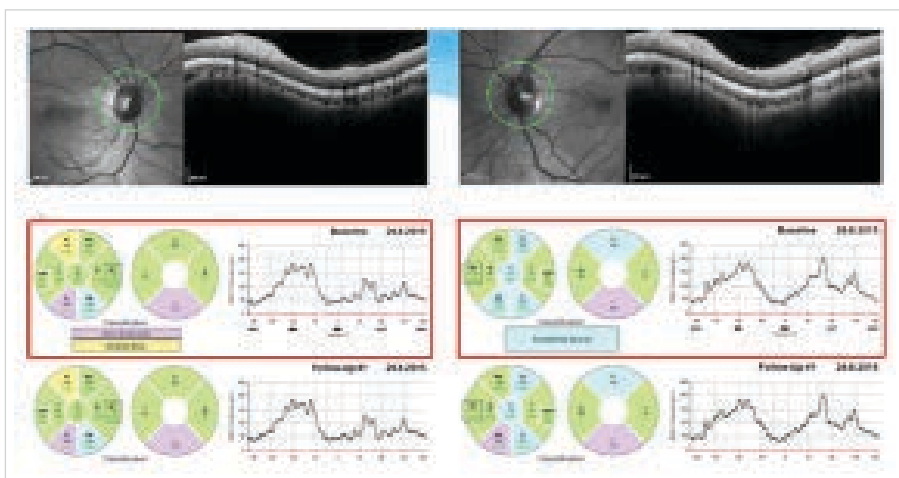


Fig. 11 Measurement of thickness of retinal nerve fibre layer (RNFL) on optical coherence tomography Heidelberg Spectralis documenting practical normalisation of thickness of RNFL bilaterally

sting approximately six months accompanied with a feeling of defocussing of vision. At the attending physician's surgery suspected papilloedema of the ON bilaterally was determined. In October 2014 the patient was sent to the outpatient clinic at the Department of Ophthalmology, University Hospital Plzeň, for evaluation of the ocular finding. Central visual acuity in both eyes was 1.0 naturally. Intraocular pressure was bilaterally within the norm. At our centre we confirmed papilloedema of the ON with an otherwise normal finding in both eyes and on the perimeter we identified relative and absolute blind spots around the Marriott point and a number of isolated non-specific blind spots in the visual field of both eyes. Through sonography of the proximal part of the ON we practically excluded the possibility of ON drusen.

On CT of the head with a contrast substance performed in October 2014, with reference to the patient's age freer subarachnoid spaces were described above the frontal lobes bilaterally, otherwise according to CT without pathological changes.

After CT of the head and our examination, suspicion of IIH was stated, MR of the head and LP were ordered at the Department of Neurology.

On MR of the head empty sella, venous angiomas on right side frontobasally, mediotemporally and in the right brain hemisphere were described. The other finding on

the brain was within the norm.

With regard to the anamnesis and objective finding, a diagnosis of IIH was determined at the Department of Ophthalmology, University Hospital Plzeň, and acetazolamide therapy was commenced in a dose of 750 mg/day. At LP at the Department of Neurology, University Hospital Plzeň, high effusion pressure of 600 mm Hg of laboratory physiological coliolymph was determined. After an agreement with us the neurologist increased the dose of acetazolamide to 1 500 mg/day. At present the patient is attending regular follow-up examinations at monthly intervals at the Departments of Ophthalmology and Neurology, University Hospital Plzeň. With regard to the fundamental improvement in headaches and regressing papilloedema of ON, the dose was reduced in November 2015 to 1 000 mg/day and in December 2015 to 750 mg/day. At the last follow-up examination in January 2016 the patient had a normal ocular finding and is practically without headaches. With regard to the development, in the coming months we are planning a further reduction of the dose of acetazolamide. Regression of the finding is evident both in fundoscopy, where a bordering of the disc of the ON occurred, and upon measurement of the RNFL with a progressive reduction of thickness, signalling a subsidence of edema during treatment, see image below. The original

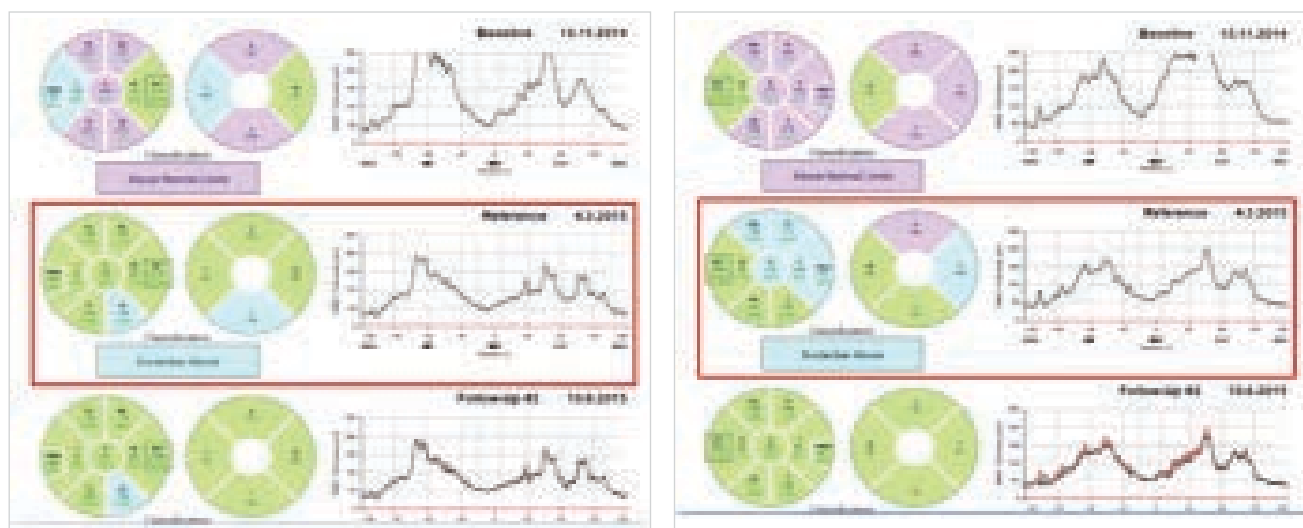


Fig. 12 Individual measurements of thickness of retinal nerve fibre layer on optical coherence tomography from commencement of treatment for idiopathic intracranial hypertension with original image of papilloedema up to complete regression of ocular symptoms (right eye on left image)

extension of the blind spot to the FF 81 perimeter bilaterally has entirely disappeared and at present the patient has a physiological VF. The patient has managed to reduce her body weight by six kilograms.

DISCUSSION

Despite the fact that IIH is primarily a neurological disorder, the role of the ophthalmologist in the diagnosis and monitoring of the development of the condition is essential. The disorder usually manifests itself in headaches, feelings of scratching in the head, nausea and tinnitus. Of the subjective complaints, very important is the information relating to headaches and their intensity, which should decrease with the regression of the disorder. Also of fundamental significance is the ophthalmological symptomatology, incorporating especially subjectively stated photopsia, blurred vision, diplopia and pain in the area around the eyes, most frequently bilateral retrobulbar. It is precisely due to frequent ocular complaints that the patient seeks medical attention at the outpatient ophthalmology clinic. In the majority cases there is usually an objectively present defect of the VF with normal or only minimally deteriorated central visual acuity. According to Wall a defect was recorded on the automated perimeter in 92% of patients (21). In approximately one third of cases there is horizontal diplopia and in 10-20% paresis of the 6th head nerve is diagnosed (22). Upon fundoscopy we find a bilateral image of papilloedema of the ON of various degrees. In the case of suspicion of IIH we can use the designation papilloedema. The term papilloedema in the Czech nomenclature is reserved only for saturation of the disc of the ON upon intracranial hypertension (15). The degree of edema of the disc of the optic nerve can be evaluated subjectively upon fundoscopy with the help of a modified Frisen scale (6, 17). Before the use of OCT ophthalmologists had no other option than subjective observation

of the disc of the ON, thus examination required considerable experience and the actual observation of the development of the swelling on the papilla was difficult to quantify. Today, thanks to the possibility of measuring the structures of the retina and optic nerve, it is possible to estimate the development of edema on the papilla more precisely. In time it is possible to compare the measurement values of peripapillary RNFL and thus better assess how edema of the ON develops. We use measurement of the thickness of the RNFL circular around the disc of the ON as a correlate of the degree of edema. The value of the first measurement of RNFL presents not only the current degree of edema but also becomes the baseline value according to which we compare the development of ON papilloedema through further measurements of the RNFL, and thus the further development of the disorder. We assess the development of ON papilloedema always together with the clinical finding. A drawback of the OCT method is the impossibility of differentiating the degree of edema in proportion to the atrophic damaged fibres of the ganglion cells. RNFL thickness is only a number stating the dimensions, and not the quality of the observed layer. According to certain studies, OCT is precise upon milder edemas of the disc. Upon massive edema the measurement values are less precise (17, 18). In the case of pronounced edemas it is more precise to use measurement of entire retinal thickness (17). OCT is most effective especially in situations where we are not capable of deciding on the basis of the ophthalmoscopic finding whether this concerns a genuine edema or merely a blurred edge of the papilla (hyperopic papilla, papilla in childhood age, fibrae medullares). We can better differentiate disc drusens using ultrasound. In connection with an anamnesis typical for increase of intracranial pressure, even minimal papilloedema measured on OCT may indicate a circumstance that could otherwise be overlooked. Measurement of the retinal layers is also significant in order to demonstrate atrophy

of the fibres of the ON generated upon IIH. Atrophy is not necessarily evident ophthalmoscopically, but upon measurement on OCT we can detect thinning of the retinal layers. This measurement is significant only after complete regression of edema of the ON disc (23). Upon IIH there is also a significant reduction in the thickness of the macula (14).

In differential diagnostics it is necessary to keep in mind that a patient with bilateral papilloedema may have intracranial hypertension caused by another serious pathological process in the brain. Timely planning of the graphic examination of the head is essential above all for this reason. In differential diagnostics it is necessary to exclude hypertonic neuropathy of the optic nerve, which is not necessarily always accompanied by further characteristic symptoms on the retina. Bilateral papillitis or intraocular neuritis rank among the less probable diagnoses. After the processing of the anamnesis and objective examination described above, we send the patient for the performance of an imaging examination of the head and a neurological consultation. If the graphic examination of the head is without a pathological finding and the anamnesis corresponds to IIH disorder, we indicate LP. The effusion pressure of the coeliolymph fundamentally contributes to the confirmation of the diagnosis, in which normal values are 100-180 mm H₂O (8-15 mmHg) measured with patient lying on the side and 200-300 mm H₂O (16-24 mmHg) measured in sitting position (1). Upon IIH the measured values are generally higher. In laboratory examination the coeliolymph is normal. The expected diagnosis usually confirms the result of the LP and neurological examination, and we commence treatment on patients. We usually begin by administering acetazolamide in a dose of up to 1 g per day divided over the course of the day. The dose can be increased up to 4 g per day. In the case of uncertainty upon evaluating the development of IIH on the background of the ophthalmological finding within the context of the development of the clinical picture, it is possible to request the neurologist for a control lumbar puncture. The value of effusion pressure of coeliolymph is still information that fundamentally contributes to an evaluation of the development of the disorder. In the case that the patient does not respond to conservative therapy, it is possible to repeat lumbar puncture a number of times. Neurosurgical intervention may be considered in the form of a ventriculoperitoneal or vertebral peritoneal shunt. Decompression of the casings of the ON, referred to by Jirásková (9, 10, 11) may also be a valuable contribution. Shunt and decompression of the casings of the optics can also be combined (7). It is also necessary to discuss and draw attention to the rare but real possibility that we will not measure a pathologically increased value upon

measurement of the effusion pressure of the coeliolymph. This may occur on the basis of an incorrect measuring technique or upon failure of the manometer upon measurement of intracranial pressure. A false negative result should not lead to an abandonment of the diagnosis, especially in the case that clinical suspicion of IIH persists in the patient, and in this case it is necessary to repeat the measurement of intracranial pressure. No examination method including LP and OCT is 100% sensitive to demonstrating IIH, nevertheless measurement of intracranial pressure is the main and most important objective method that assists determining a diagnosis of IIH. In case report 1 the above hypothesis was confirmed. In certain patients we also do not observe, and even with the help of OCT do not demonstrate edema of the ON disc despite ongoing IIH confirmed by the neurological examination and clinical development. The presence of papilloedema of the ON points to possible intracranial hypertension, but the absence of papilloedema does not exclude intracranial hypertension (19). In these cases also the participation of an ophthalmologist and an examination of visual functions upon observation of the further development is essential.

CONCLUSION

OCT is a method which brings the possibility of referential graphic and numerical quantification to the diagnosis of ON disc edema through the measurement of retinal structures. Through a comparison of the measured values it is then possible to observe the development of the ON disc edema over time. In the ophthalmological finding disc edema is of key importance not only for determining a diagnosis of IIH but also for further observation of the development of the disorder. OCT may play a fundamental role in equivocal cases, in which we could overlook or underestimate edema. Even despite imprecision upon measurement of the peripapillary structures of the retina in the case of a massive papilloedema of the ON, it is possible to assess the success of treatment from a reduction of the values of edema in correlation with the clinical picture. IIH can be treated pharmacologically, and in the case of necessity a surgical procedure is indicated. However, reduction of the patient's body mass is of fundamental significance for improving the patient's condition. IIH is a pathology with a risk of severe damage to sight and a pronounced negative influence on the patient's quality of life. With regard to this fact, the development of further co-operation between ophthalmologists and neurologists, as well as the search for new diagnostic methods and the improvement of established ones, is highly necessary.

LITERATURA

1. **Agamanolis DP.**: Chapter 14 - Cerebrospinal Fluid: The normal CSF. Neuropathology. An illustrated interactive course for medical students and residents [online]. Leden 2013 [cit. 25. března 2016]. Dostupné na: [WWW:<http://neuropathology-web.org/chapter14/chapter14CSF.html>](http://neuropathology-web.org/chapter14/chapter14CSF.html).
2. **Corbett JJ.**: Problems in the diagnosis and treatment of idiopathic intracranial hypertension. *Can J Neurol Sci*, 1983;10:221-9.
3. **Corbett JJ, Savino PJ, Thompson HS, et al.**: Visual loss in pseudotumor cerebri. Follow-up of 57 patients from five to 41 years and a profile of 14 patients with permanent severe visual loss. *Arch Neurol*, 1982; 39: 461-474.
4. **Durcan FJ, Corbett JJ, Wall M.**: The incidence of pseudotumor cerebri. Population studies in Iowa and Louisiana. *Arch Neurol*, 1988; 45: 875-877.
5. **Friedman DI, Jacobs DM.**: Diagnostic criteria for idiopathic intracranial hypertension. *Neurology*, 2002; 95:1492-5.
6. **Frisén L.**: Swelling of the optic nerve head: a staging scheme. *J Neurol Neurosurg Psychiatr*, 1982; 45: 13-18.
7. **Hlaváčová P, Vlčková E.**: Benefit chirurgické léčby idiopatické intrakraniální hy-

- pertenze -kazuistické sdělení. Čes Slov Oftalmol, 2009; 65: 195–8.
8. **Jirásková N, Rozsival P.:** Idiopathic intracranial hypertension in pediatric patients. *Clin Ophthalmol*, 2008; 2(4): 723–6.
 9. **Jirásková N, Rozsival P.:** Dekomprese pochev zrakového nervu. Čes Slov Oftalmol, 1995; 51: 254–7.
 10. **Jirásková N, Rozsival P.:** Dekomprese pochev zrakového nervu – výsledky u prvních 37 operovaných očí. Čes Slov Oftalmol, 1996; 52: 297–307.
 11. **Jirásková N, Rozsival P.:** Výsledky 62 dekompresí pochev zrakového nervu. Čes Slov Oftalmol, 1999; 55: 136–44.
 12. **Jirásková N.:** Idiopatická intrakraniální hypertenze (pseudotumor mozku). Čes Slov Oftalmol, 2000; 56: 262–5.
 13. **Michael W.:** Idiopathic Intracranial Hypertension. *Neurol Clin*. 2010; 28(3): 593–617.
 14. **Monteiro ML, Afonso CL.:** Macular thickness measurements with frequency domain-OCT for quantification of axonal loss in chronic papilledema from pseudotumor cerebri syndrome. *Eye (Lond)*, 2014; 28(4): 390–8.
 15. **Otradovec J.:** Klinická neurooftalmologie. 1. vydání. Praha: Grada Publishing 2003.
 16. **Radhakrishnan K, Ahlskog JE, Cross SA, et al.:** Idiopathic intracranial hypertension (pseudotumor cerebri). Descriptive epidemiology in Rochester, Minn, 1976 to 1990. *Arch Neurol*, 1993; 50: 78–80.
 17. **Scott CJ, Kardon RH, Lee AG, et al.:** Diagnosis and Grading of Papilledema in Patients with Raised Intracranial Pressure Using Optical Coherence tomography vs clinical expert assessment using a clinical staging scale. *Arch Ophthalmol*, 2010; 128(6): 705–11.
 18. **Skau M, Sander B, Milea D, et al.:** Disease activity in idiopathic intracranial hypertension: a 3-month follow-up study. *Neurol*, 2011; 258(2): 277–83.
 19. **Unsöld R.:** Ophthalmological symptoms of idiopathic intracranial hypertension: Importance for diagnosis and clinical course. *Ophthalmologe*, 2015; 112(10): 808–13.
 20. **Wall M, Hart WM, Jr., Burde RM.:** Visual field defects in idiopathic intracranial hypertension (pseudotumor cerebri). *Am J Ophthalmol*, 1983; 96: 654–669.
 21. **Wall M, George D.:** Visual loss in pseudotumor cerebri. Incidence and defects related to visual field strategy. *Arch Neurol*, 1987; 44: 170–175.
 22. **Wall M, George D.:** Idiopathic intracranial hypertension. A prospective study of 50 patients. *Brain*, 1991; 114: 155–180.
 23. **Yri HM, Wegener M, Sander B, et al.:** Idiopathic intracranial hypertension is not benign: a long-term outcome study. *J Neurol*, 2012; 259(5): 886–94.