

Posterior Fossa Abscess with Obstructive Hydrocephalus in a Child with Occipital Dermal Sinus with Dermoid Cyst Manifestation – a Case Report

Absces zadní jámy lební s obstrukčním hydrocefalem u dítěte s dermoidální cystou s dermálním sinusem – kazuistika

Abstract

Posterior fossa dermoid cysts with dermal sinuses are rare cerebral tumours. Authors recently treated a 7-month-old girl who suffered from a posterior fossa dermoid cyst with dermal sinus. In addition, cerebellar abscess in the left cerebellar hemisphere was detected by CT and MRI. Surgery was performed the day after external ventricular drainage insertion, and the dermoid cyst and cerebellar abscess were fully excised. Early detection and adequate management of these benign tumours can prevent serious complications, as argued within the discussion section.

Souhrn

Dermoidální cista s dermálním sinusem v oblasti zadní jámy lební je málo častým mozkovým nádorem. Autoři uvádí kazuistiku sedmiměsíční pacientky léčené pro dermoidální cystu s dermálním sinusem v oblasti zadní jámy lební spolu s mozečkovým abscesem, detekovaným CT a MR vyšetřením. Pacientka byla operována den po zavedení zevní komorové drenáže; byla provedena totální excize dermoidální cystal a mozečkového abscesu. Včasná diagnóza a správný postup ošetření těchto benigních mozkových tumorů mohou zabránit závažným komplikacím, jak je dále rozvedeno v diskuzi.

The informed parental consent for publication of this case report was obtained.

The authors declare they have no potential conflicts of interest concerning drugs, products, or services used in the study.

Autoři deklarují, že v souvislosti s předmětem studie nemají žádné komerční zájmy.

The Editorial Board declares that the manuscript met the ICMJE "uniform requirements" for biomedical papers.

Redakční rada potvrzuje, že rukopis práce splnil ICMJE kritéria pro publikace zasílané do biomedicínských časopisů.

E. Brichtova¹, F. E. B. Q. Azevedo²

¹ Department of Neurosurgery, Masaryk University Medical School, St. Anne University Hospital in Brno

² Masaryk University Medical School



Brichtova Eva, M.D., Ph.D., Assoc. Prof.
Department of Neurosurgery
Masaryk University Medical School
St. Anne University Hospital in Brno
Pekarska 664/53
656 91 Brno
e-mail: brichtovae@seznam.cz

Accepted for review: 21. 10. 2014

Accepted for print: 26. 2. 2015

Key words

dermoid cyst – mature teratoma – dermal sinus – cerebellar abscess

Klíčová slova

dermoidální cista – vyzrálý teratom – dermální sinus – mozečkový absces

Introduction

Dermoid cysts are among the rarest of intracranial tumours, representing 0.3% of intracranial tumours [1]. They tend to manifest at an early age, during childhood

and adolescence, due to large production of oil within the lesion, resulting in a large mass lesion. These tumours are known to develop during early embryonic development of the neural tube (3rd and 5th week of gestation),

at which time cutaneous tissue cells are sequestered within the neural tube to form an intradural dermoid cyst. They tend to form lines of the neuraxis and vertebral canal in the midline along posterior closure,

from displaced cellular elements with cutaneous commitments [1]. The posterior fossa is a rare but recognized site for dermoid development [2]. These posterior fossa dermoid cysts can be divided into four categories based on the following two criteria: 1. anatomical situation (intradural or extradural) 2. degree of occipital dermal sinus development (absent, partial or complete) [3]. Patients with a posterior fossa dermoid cyst and an associated dermal sinus may develop bacterial meningitis or abscess of the dermoid itself [4]. Embryogenesis explains why these tumours most commonly appear in the midline, most frequently near the fourth ventricle (one third of the lesions), spine (especially in the first year of life when they account for 17% of primary spinal tumours), third ventricle or even base of the brain. Lesions in the cauda equina and the cerebellar vermis are often associated with a dermal sinus [1]. These cranial dermal sinuses were first described by Ogle in 1865 [5].

Case report

We report a case of a paediatric patient with abscessing posterior fossa dermoid cyst with dermal sinus. A 7-month-old girl was admitted to our department with fever lasting three days and signs of increased intracranial pressure (vomiting with elevated anterior fontanelle). She also had

a small oedema at her occipital region that occurred at three months of age, ruptured spontaneously 10 days before the admission; the rupture was followed by purulent secretion. CT scan showed decompensated obstructive hydrocephalus, lobulated, cystic space occupying a lesion in the posterior fossa midline and a midline defect at the occipital bone region (suggesting the possibility of dermal sinus). Blood analysis revealed an elevated C reactive protein level and leucocytosis. Neurological examination revealed paresis of the left abducens nerve. The patient underwent emergency surgery to manage the decompensated obstructive hydrocephalus and external ventricular drainage was inserted into the frontal horn of the right lateral ventricle. Antibiotic treatment with ceftriaxon (Rocephin) and amikacine (Amikin) was administered intravenously. Subsequent MRI revealed several cerebellar abscesses with a dermoid cyst and a complete dermal sinus (Fig. 1). The patient underwent definitive operative treatment for the abscessing dermoid cyst in the posterior fossa with spreading to the fourth ventricle and associated complete dermal sinus (Fig. 2). Postoperative MRI showed that the tumour was totally removed (Fig. 3). Histological examination of surgical specimens confirmed the diagnosis of mature teratoma (Fig. 4). Bacteriological cultures from specimens were positive for

Staphylococcus aureus and the treatment with oxaciline (Prostaphlin) was initiated. Postoperative clinical course was very positive. Obstructive hydrocephalus regression allowed removal of the external ventricular drainage 10 days post-surgery. The girl was discharged from the hospital seven days later. She underwent further rehabilitation and six months after the surgery her psychomotor skills were within the normal range. As the left abducent nerve paresis slightly persisted, the patient underwent another surgery one year later to correct the paresis.

Discussion

Dermoid cysts are true ectodermal inclusion lesions lined with epithelium, composed of various amounts of well-differentiated ectodermal and mesodermal elements (endodermal elements are usually not observed, these are more suggestive of a germ cell tumour). Some of these ectodermal inclusions may be hair follicles, sebaceous glands or even sweat glands. The majority of congenital dermoid tumours probably develop during the early stages of development, between the 3rd to 5th week of gestation. The presence of another associated congenital anomaly in 50% of patients with dermoid cysts is suggestive of a midline fusion defect. According to the available literature, dermoid cysts are not

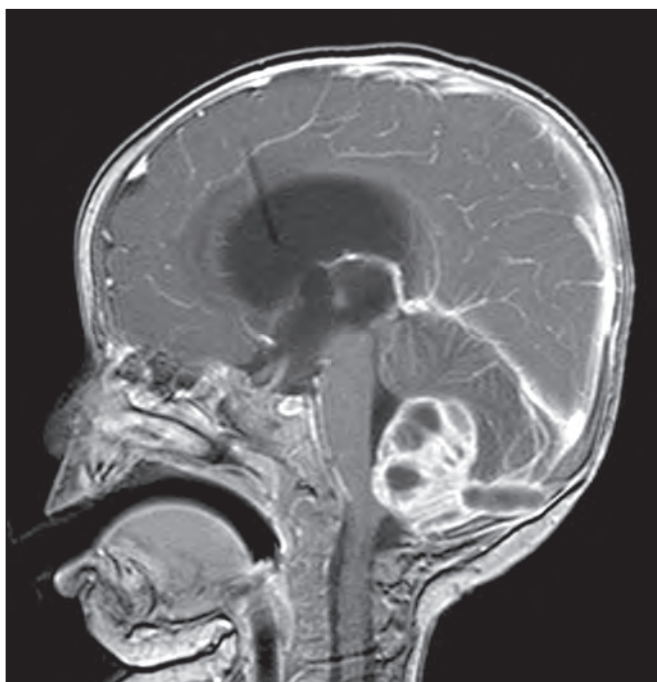

Fig. 1. Sagittal MRI section showing a cerebellar mass lesion communicating subcutaneously through the occipital bone defect.

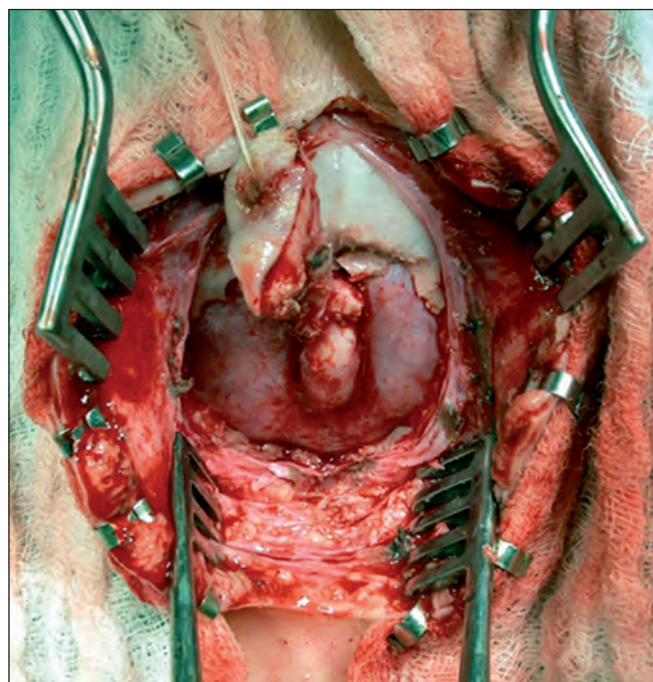


Fig. 2. Congenital dermal sinus tract through the occipital bone terminating in the intradural dermoid cyst.

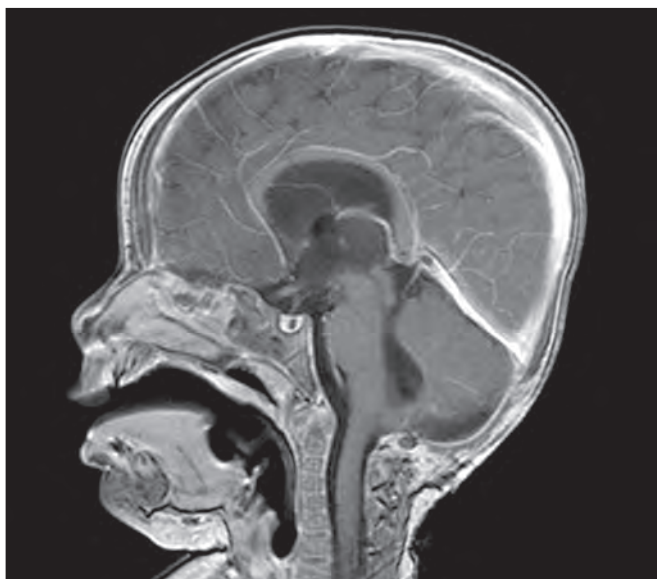

Fig. 3. Postoperative sagittal MRI section.

only congenital but also iatrogenic (e.g. due to lumbar puncture performed with an open needle) or traumatic (e.g. due to a stab or puncture wound), occurring as a consequence of an implantation of skin elements from the surface into underlying tissues. This type of a cyst may occur at any age but much less commonly than the congenital one [6]. At present, CT and MRI scans are both used for the diagnosis of this tumour. CT images the dermoid cyst as a hypodense lesion, not enhancing after a contrast agent administration, unlike abscesses that, if present, are more dense and their capsule is markedly enhanced by a contrast agent. CT bone window is used for bone defects detection. Defects not diagnosed with CT (axial slices may miss it) can be identified with MRI, especially with sagittal plane sections that show the typically oblique stalk that links the cyst with the skin [7]. Dermoid cysts tend to show an increased signal intensity on both T1 and T2-weighted MRI images and a low signal intensity on STIR images [8], although a ruptured cyst may be hypointense on T1-weighted images and hyperintense on T2 [8]. Posterior fossa dermoid cysts may be divided into four types: extradural dermoid cysts with a complete dermal sinus, intradural dermoid cysts without a dermal sinus, intradural dermoid cysts with an incomplete dermal sinus and, as in our case, intradural dermoid cyst with a complete dermal sinus [3]. Intradural dermoid cysts with a complete dermal sinus are difficult

to manage since they communicate with the skin and this promotes microbial colonization [9]; this introduces a risk of deeper suppuration [5] and abscess formation. Mortality and morbidity increases significantly in patients with bacterial or chemical meningitis [10]. Total microsurgical excision is the only treatment known to be effective in patients with dermoid cysts. The surgery has to be performed so that it avoids cerebrospinal fluid (CSF) contamination or rupture of the cyst into the ventricles [11]. Maximal but incomplete resection of the dermoid cyst wall is preferred in case of close approximation to adjacent nerves and vessels. Benign course of these tumours and the slow regrowing rate of remaining dermal cells most commonly will not lead to a clinically symptomatic recurrence. Since these methods have been adopted, the risk of mortality decreased from 70% in the 30s (Bailey 1920; Sweet 1940) to around 5% [1]. When a dermal sinus penetrates the occipital region, perioperative care must be taken to avoid a rapid and fatal exsanguination due to a possible connection with the cranial venous confluence [9]. If cerebellar abscesses are present, aspiration should not be performed since it might cause dissemination of an encapsulated lesion through the puncture site and may even produce haemorrhage with compression or shift of adjacent brainstem structures [12]. Since postoperative meningitis is one of the most common complications of this neurosurgery excision, broad-spectrum intravenous antibiotics should be admin-

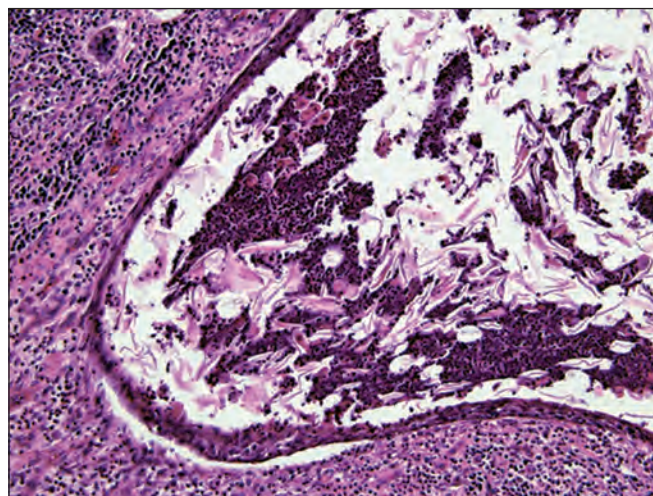


Fig. 4. Histological examination of dermoid cyst with preserved epithelium and inflammatory cells (HE, 200x).

istered until the specific pathogen is cultured and corresponding antibiotic sensitivity is identified. In our case, since the child presented with the signs of decompensated hydrocephalus (vomitus, elevated anterior fontanel, CT finding), external ventricular drainage was inserted to alleviate the elevated intracranial pressure and to promote more favourable surgery conditions (and perhaps to decrease the need for permanent CSF derivation). Hydrocephalus is the second most common presentation of dermoid cysts after infection and may be present due to the CSF circulation obstruction or secondarily due to an infection [11,13].

Conclusion

When a depression, subcutaneous swelling or skin or hair exudate occurs in the occipital region, an experienced practitioner should be sought in order to avoid misdiagnosis and potential complications of the dermoid cysts (such as meningitis, cerebellar abscesses, obstructive hydrocephalus or adhesions to adjacent brain structures). MRI scans are very helpful for the diagnosis of these lesions and to plan surgery. Neurosurgical microexcision is the only effective treatment for dermoid cysts with dermal sinuses. Postoperative meningitis can be prevented with intravenous administration of antibiotics.

Reference

1. Kavar BH, Kaye A. Dermoid, epidermoid and neurenteric cysts. In: Kaye A, Laws E (eds). Brain Tumors: An encyclopaedic approach. 3rd ed. Chapter 43. New York: Elsevier 2012.

2. Cobbs CS, Pitts LH, Wilson CB. Epidermoid and dermoid cysts of the posterior fossa. *Clin Neurosurg* 1997; 44: 511–528.
3. Logue V, Till K. Posterior fossa dermoid cysts with special reference to intracranial infection. *J Neurol Neurosurg Psychiatr* 1952; 15(1): 1–12.
4. Hsu ST, Lee YY, Chao SC, Hsieh MY, Huang CC. Congenital occipital dermal sinus with intracranial dermoid cyst complicated by recurrent *Escherichia coli* meningitis. *Br J Dermatol* 1998; 139(5): 922–924.
5. Aryan HE, Jandial R, Farin A, Chen JC, Granville R, Levy ML. Intradural cranial congenital dermal sinuses: diagnosis and management. *Childs Nerv Syst* 2006; 22(3): 243–247.
6. Smirniotopoulos J, Chiechi MV. Teratomas, dermoids and epidermoids of the head and neck. *RadioGraphics* 1995; 15(6): 1437–1455.
7. Tekkok IH, Baesa SS, Higgins MJ, Ventureyra EC. Abscedation of posterior fossa dermoid cyst. *Childs Nerv Syst* 1996; 12(6): 318–322.
8. Caldarelli M, Massimi L, Kondageski C, Di Rocco C. Intracranial midline dermoid and epidermoid cysts in children. *J Neurosurg* 2004; 100 (Suppl 5): 473–480.
9. Güzey FG, Bas NS, Sencer A, Emel E, Hamamcioglu MK, Ozkan N et al. Posterior fossa dermoid cysts causing cerebellar abscesses. *Pediatr Neurosurg* 2007; 43(4): 323–326.
10. Douvoyiannis M, Goldman DL, Abbott IR, Litman N. Posterior fossa dermoid cyst with sinus tract and meningitis in a toddler. *Pediatr Neurol* 2008; 39(1): 63–66. doi: 10.1016/j.pediatrneurol.2008.03.019.
11. Çirak B, Kiyamaz N, Kerman M. Cerebellar dermoid cysts with hydrocephalus. *J Pediatric Neurol* 2004; 2(3): 161–164.
12. Akhaddar A, Jiddane M, Chakir N, El Hassani R, Moustarchid B, Bellakhdar F. Cerebellar abscesses secondary to occipital dermoid cyst with dermal sinus: case report. *Surg Neurol* 2002; 58(3–4): 266–270.
13. Cai CQ, Zhang QJ, Hu XL, Wang CX. Dermoid cyst of the posterior fossa associated with congenital dermal sinus in a child. *World J Pediatrics* 2008; 4(1): 66–69. doi: 10.1007/s12519-008-0014-x.

Projekt ncRNAPain

Rádi bychom vás informovali o projektu ncRNAPain, který bude zkoumat ncRNAs specificky u vybraných klinických jednotek provázených neuropatickou bolestí – zejména u bolestivé diabetické neuropatie (pDPN), traumatických neuropatií a chronického regionálního bolestivého syndromu (CRPS) s cílem získat poznatky o mechanismech chronické bolesti.

Na základě porozumění mechanismů indukce a udržení chronické bolesti a přenosu výsledků preklinického a klinického výzkumu do klinické praxe zlepši kvalitu života nemocných a sníží celospolečenskou zátěž způsobenou chronickou bolestí v Evropě.

Projekt je podporován ze 7. rámcového programu EU, na kterém se podílí řada center ostatních evropských zemí (Dánsko, Francie, Německo, Rakousko, Velká Británie) a Izraele.

Trvání projektu: 1. 11. 2013–31. 10. 2017.

Kteří pacienti a zdraví dobrovolníci se mohou účastnit výzkumu?

- pacienti s cukrovkou 1. nebo 2. typu a bolestivou nebo nebolestivou formou diabetické neuropatie (ať už prokázanou nebo při podezření na tuto komplikaci cukrovky),
- pacienti s poraněním periferního nervu déle než 3 měsíce od úrazu,
- zdraví dobrovolníci netrpící chronickou bolestí ve věku 40–70 let.

Výzkum bude probíhat v 1. fázi na Neurologické klinice Fakultní nemocnice Brno.

Pro více informací o projektu a pro ověření vhodnosti kandidáta k účasti ve studii, kontaktujte prosím:

Jana Novohradská

laborantka

E-mail: neuropain@seznam.cz

Telefon: +420 733 165 191

Pacientům a dobrovolníkům účast v projektu umožní kromě podílení se na zajímavém a špičkovém výzkumu, jehož výsledky mohou zásadně ovlivnit léčbu chronické bolesti, také upřesnění stupně a typu postižení periferních nervů a v případě zájmu zejména u bolestivé formy následná konzultace stran optimální léčby.

*prof. MUDr. Josef Bednařík, CSc., FCMA
garant projektu*